

**Review Article**

**EXPERIENCE OF SUCCESSFUL THORACOSCOPIC PERICARDECTOMY OF EXUDATIVE PERICARDITIS WITH COMPRESSION SYNDROME AND THE THREAT OF CARDIAC TAMPONADE**

<sup>1</sup>Adkham Kasimov, <sup>2</sup>Bakhtiyorjon Matkarimov, <sup>3</sup>Sarvarjon Salahidinov, <sup>4</sup>Gayratbek Saliev, <sup>5</sup>Doniyorbek Khasanov, <sup>6</sup>Dilfuzahon Mamarasulova

<sup>1</sup>MD, Associate Professor, Department of General Surgery, Andijan State Medical Institute, Uzbekistan.

<sup>2</sup>Ph.D., Academician, Associate Professor, Department of General Surgery of the Andijan State Medical Institute, Resident Physician of the 2nd Surgical Department of the Clinic, Andijan State Medical Institute, Uzbekistan.

<sup>3</sup>Candidate of Medical Sciences, Associate Professor, Head of the Department of General and Military Surgery, Andijan State Medical Institute, Uzbekistan.

<sup>4</sup>Assistant of the Department of General Surgery of the Andijan State Medical Institute, Uzbekistan.

<sup>5</sup>Candidate of Medical Sciences, Associate Professor, Department of Oncology and Medical Radiology, Andijan State Medical Institute, Uzbekistan.

<sup>6</sup>MD, Associate Professor, Head of the Department of Oncology and Medical Radiology, Andijan State Medical Institute, Uzbekistan.

E-mail address: matkarimov1973@mail.ru

Received: 03.12.2019

Revised: 09.01.2020

Accepted: 15.02.2020

**Abstract**

This scientific article describes the case of successful performance of a thoracoscopic pericardectomy in a 72-year-old patient about exudative pericarditis with compression syndrome and with the threat of cardiac tamponade. Pericarditis is an inflammation of the serous membrane of the heart. According to the form of clinical manifestations of pericarditis emit: acute, subacute and chronic. Depending on the nature of the inflammatory process, there are fibrinous and exudative pericarditis with the presence of serous, serous-fibrinous, purulent, fibrinous-purulent and hemorrhagic effusion. Patients with the threat and development of cardiac tamponade with purulent and constrictive pericarditis were shown surgical intervention. As a result, a thoracoscopic pericardectomy with a good clinical and cosmetic effect was performed. The clinical case is interesting using a minimally invasive technique. When a patient has exudative pericarditis, pericardectomy in the immediate postoperative period has led to good results, which was an effective method of treatment for this pathology. As a result, we concluded that the thoracoscopic pericardectomy method is an alternative to thoracotomy and sternotomy. The use of minimally invasive treatment of pericarditis can be a promising method and requires further study of long-term results.

**Keywords:** pericarditis, thoracoscopy, pericardectomy, thoracoscopic fenestration, cardiac tamponade, cardiac compression syndrome, echocardiography, pericardial resection.

© 2019 by Advance Scientific Research. This is an open-access article under the CC BY license (<http://creativecommons.org/licenses/by/4.0/>) DOI: <http://dx.doi.org/10.31838/jcr.07.04.70>

**INTRODUCTION**

According to WHO, pericardial effusion (EP) in most cases is a secondary disease, which can be caused by an infection, tumors, autoimmune processes, trauma, in some patients (EP) is the first and only manifestation of systemic disease. In some cases, the cause of pericarditis is unknown. Signs of active or past pericarditis is found at autopsy in 3-6,1% of all postmortem studies [12,13,18].

The most severe complication (EP) is the cardiac tamponade, life-threatening patient [11]. All this leads to the importance of studying this disease. Surgical treatment is indicated in the threat and the development of cardiac tamponade, purulent and constrictive pericarditis. Questions of method and volume of surgical intervention when pericarditis is still being discussed. For the purpose of heart decompression drainage, and sanitation of a cavity of the pericardium at (EP) many methods of treatment such as pericardiocentesis [8], extrapleural pericardiotomy, resection of the pericardium [11,18], thoracoscopic fenestration and [4], subtotal resection of the pericardium are currently used.

As a rule, the authors used only a single treatment and only in some clinics apply a selective approach to correcting this pathology. Pericardiocentesis and drainage of the pericardial cavity can be effective only in the early stages of the disease [2]. In the later stages of the process these methods of decompression, drainage, and sanitation the pericardial cavity are often less effective, and despite the relief of acute

inflammation, later often develop constrictive pericarditis requiring pericardectomy [16].

These complications associated with the transition of the inflammatory process in the productive stage and formation of intrapericardial junctions and the presence of thick tightly fixed on the infiltrated leaves of the pericardium fibrinous-purulent exudates [9,13]. Pericardectomy is an effective method of treatment of purulent and fibrous-purulent pericarditis and is recommended by many authors, both early and late stages of the disease [7]. Currently, video-assisted thoracoscopic sanitation of the pleural cavity has become the method of choice in the treatment of purulent pleurisy and empyema (3). The benefits of minimally invasive operations and good visualization was a prerequisite for the use of thoracoscopy for the treatment of pericarditis. However, some clinics perform a thoracoscopic method, only the fenestration of the pericardium at (EP) [4,15] that do not adequately sanitize the cavity of the pericardium and can not prevent the development of constrictive pericarditis. Thoracoscopic pericardectomy was first done in animal studies [10,12,18], and then applied in clinical practice [1,2].

Evaluation of treatment results showed that this procedure has several advantages over open pericardectomy, including decreasing postoperative pain, reducing the number of complications in the operating wound, shortening the recovery time, while achieving a good cosmetic effect.

Currently, only a limited number of reports on the

implementation of thoracoscopic pericardectomy in (EP). In some publications confirm the safety, efficiency, and low-impact of thoracoscopic pericardectomy.

The article describes the successful implementation of thoracoscopic pericardectomy the patient at the age of 72 years, suffering from (EP) accompanied with shoulder impingement syndrome and the threat of cardiac tamponade.

#### Clinical case

Here is a case of clinical observation: the patient Amanov T., 72 years old (case history No. 21613/1553) 07.12.2018 hospitalized in the department of cardiovascular surgery clinic of ASMI in a planned manner with a diagnosis of "Pericardial effusion".

Upon receipt complained of increased heartbeat, at times appear pain in the heart region and chest, accompanied by feeling short of breath, copious sputum, decreased appetite, increasing weakness and disability.

From the anamnesis data, it is established that the patient suffered for several years, was repeatedly treated in the hospital and on an outpatient basis, and was under constant supervision of a cardiologist at the place of residence. Besides, the patient was treated for several years in inpatient and outpatient settings under the supervision of a doctor and a phthisiatrician for a "specific lung disease". The patient received specific treatment for a long time and was under the supervision of specialists, and subsequently was removed from

the register of dispensary observation. In the recent general condition of the patient gradually began to deteriorate with the progression of the aforementioned subjective feelings. Conducted complex treatment measures have not led to significant improvement and were not successful. In this regard, the patient was hospitalized in a specialized to department of the cardiovascular surgery clinic of ASMI.

When applying the general condition of the patient was estimated by us as heavy due to the growth of respiratory and heart failure and the risk of cardiac tamponade. An objective examination of the motor activity of the patient is reduced, the skin pales with a grayish tinge, occasionally it was noted acrocyanosis. Respiratory rate of 22-24 per minute.

Auscultation in all parts of the lungs, hard breathing is heard. Heart sounds are rhythmic, muffled, percussion borders of the heart are expanded. Heart rate 100-108 beats/min. Hepatomegaly, liver + 2.0 cm, from the edge of the costal arch. Diuresis 500-700 ml. per day.

Several instrumental and laboratorial methods of research were carried out at the clinic

An echocardiographic examination revealed signs of expansion of the heart cavity, left ventricular hypertrophy; the right ventricle cavity is 2.9 cm, KDR-3.8 cm, KDO-63ml, KSO-26ml, PV-38%. Free fluid is visualized in the pericardial cavity, the contents are homogeneous, exudate in the amount of 800 ml. Conclusion: "Exudative secondary pericarditis" (Fig. 1).

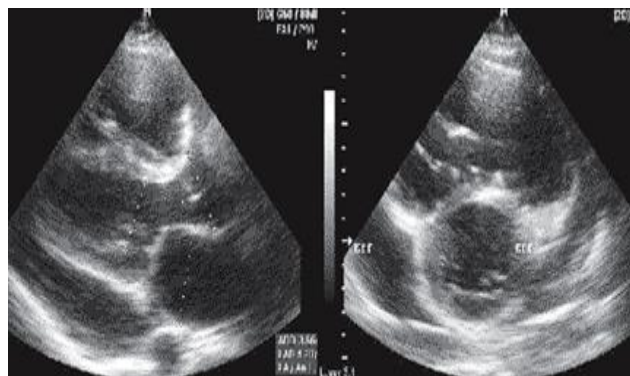


Figure. 1. Ultrasound. Exudation in the pericardial cavity.

Ultrasound of the abdominal cavity revealed signs of congestive liver and chronic stoneless cholecystitis. A chest x-ray dated 7/12/2018 showed moderate cardiomegaly and congestive bilateral pneumonia (Fig. 2).

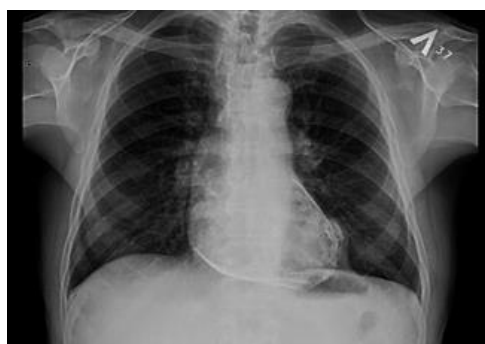

Figure. 2. Radiograph of the chest.

On ECG—sinus tachycardia and myocardial ischemia.

In the general analysis of blood: hemoglobin-80 g/l; erythrocytes-3,61x10<sup>12</sup>/l; colour index-0,7; white blood cells-11,0x10<sup>9</sup>/l; platelets-170x10<sup>9</sup>/l; stab neutrophils-3; segmented neutrophils-65; eosinophils-1; lymphocytes-30, monocytes-1; ESR - 15 mm/hour.

The results of biochemical studies of blood: bilirubin total-of 41.76 mmol/l; direct bilirubin-10.44 mmol/l; indirect bilirubin-31,32 mmol/l; total protein - 54 g/l; ALT-6.0 mmol/l; AST-4.2

mmol/l; amylase  $\alpha$ -20,5 mmol/l; sugar-7.2 mmol/l, urea 7.1 mmol/l; residual nitrogen and 3.6 mmol/l; creatinine 128 mmol/L.

In coagulogram: PTI-105%; fibrinogen in Rupert-5994mg/%; thrombotest-VI degree.

Bacterioscopic investigation of sputum for tubercle Bacillus is negative.

In the clinic, taking into account the results of

Echocardiography, ultrasound, radiography and laboratory parameters was exhibited clinical diagnosis:

Main: Pericardial effusion. Coronary heart disease. Tense stable angina, FC-2. Complication: chronic heart insufficiency, II-B degree, FC-3 by NUNA. Bilateral pneumonia, congestive. Respiratory failure of II degree. Stagnant liver. General intoxication of the organism.

The patient is assigned a complex treatment, however, due to deterioration of the general condition, which was caused by the increase of signs of cardiac and respiratory failure and the threat of cardiac tamponade patient was advised by the resuscitation and was transferred for further observation and treatment in intensive care. In the intensive care unit continued intensive treatment and surveillance, which resulted in the patient's condition has somewhat stabilized, although still retained the phenomena of cardiac and respiratory failure.

Patients underwent multislice computed tomography (MSCT) and showed signs of double hydrothorax, pulmonary fibrosis, pneumonia, congestive left, hydropericardium. Having a consultation with a specialist oncologist and the cancer is not detected. Subsequently, given the dynamics of the periodic increase and progression of cardiac and respiratory failure and cardiac tamponade after consultation with the following specialists (cardiac surgeons, intensive care specialists, cardiologists, pulmonologists and specialists endosurgery) for health reasons it was decided to produce "the vats pericardectomy".

After appropriate preparation on December 11, 2018, the "Left-sided thoracoscopic pericardectomy" was performed. The operation was carried out using modern technology, with the apparatus of the Karl Storz endosurgical video kit (Germany). The operation was performed under general endotracheal anesthesia with the left side turned off, with the right lung intubated. The patient was laid in the right lateral position. The main trocar with a diameter of 10 mm was introduced along the anterior axillary line in the 3rd and 4th intercostal space, and working instruments were introduced along the medial axillary line in the 6th and 7th intercostal space (Fig. 3.4).

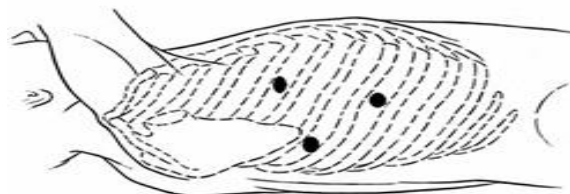


Figure. 3. Schematic representation of the puncture site.

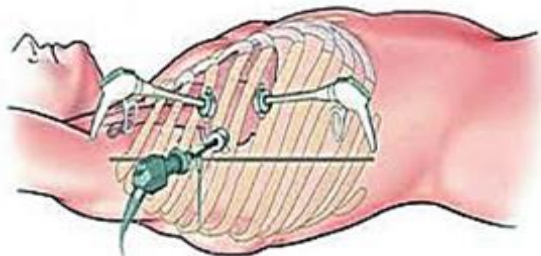


Figure. 4. Schematic representation of the puncture site.

At the time of examination, a small amount of serous effusion was noted in the pleural cavity, the pericardium was sharply thickened, hyperemic, infiltrated, and a lung was soldered loose to it. Using an electrocoagulator, the pericardium is separated from adhesions - adhesiolysis (Fig. 5).

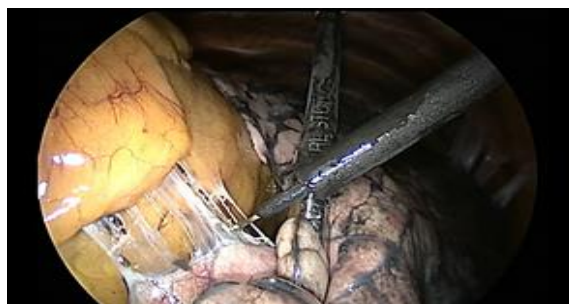

Figure. 5. The stage of separation of pericardiopulmonary adhesions.

At the opening of the pericardium, a liquid of a dark brown color ("in the form of meat slops") was jet and under pressure, and about 800-900 ml of liquid was aspirated (Fig. 6,7,8).

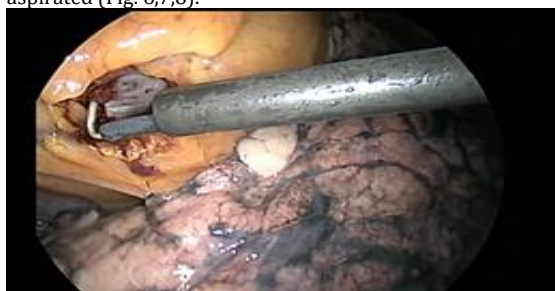

Figure. 6. Autopsy of the pericardium

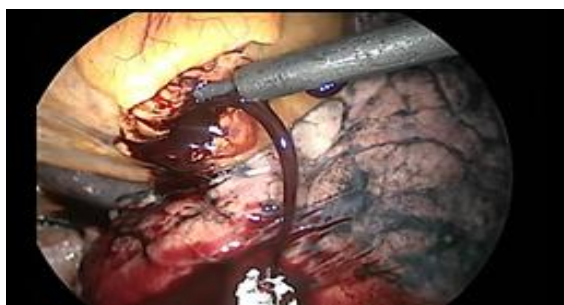

Figure. 7. Jet discharge of fluid from the pericardial cavity.

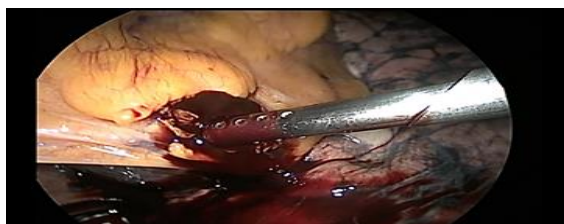

Figure. 8. Stage of aspiration.

Aspirated fluid from the pericardial cavity was sent to a clinical laboratory for cytological examination. In the pericardial cavity, there were tightly fixed grayish-colored overlays. Further, the pericardial cavity is washed with a warm antiseptic 0.02% solution of furacilin (Fig. 9).

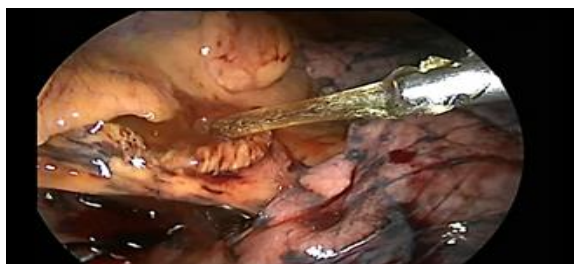
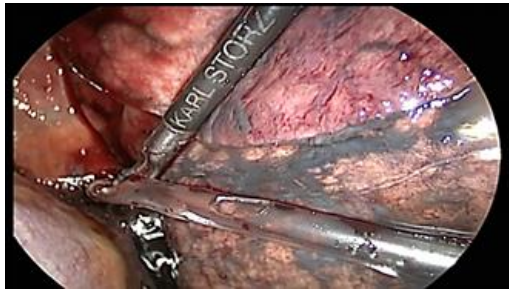
Figure. 9. Washing the pericardial cavity with a 0.02% solution of furacilin.

Performed drainage type "flow system". The first drainage tube is installed through a 5mm hole. trocar. An "outflow" drainage is installed through the lower trocar opening into the pleural cavity (Fig. 10).



**Figure.10. Drainage of the pericardial cavity and the pleural cavity.**

Imposed flow system with vacuum aspiration for washing the pericardial cavity with a warm solution of furacilin in the postoperative period. The operation was completed by the imposition of cosmetic sutures on the skin.

The results of cytological examination of pericardial contents from 12.12.2018-g: number-10ml, color-spotting, transparency turbid, reaction Rivalta-positive; protein 66,0 g/l. Microscopic data: erythrocytes-entirely; the leukocytes in large numbers; neutrophils-76%; eosinophils-21%; lymphocytes-19%. These data suggested the presence of the syndrome "systemic inflammatory response".

The postoperative management included antibiotic, cardiovascular, restorative therapy in conjunction with blood substitutes, plasma transfusion, protein drugs, and other therapeutic agents, as well as continued flow flushing the pericardial cavity within 5 days, the drainage was removed on day 7 after surgery. The general condition of the patient stabilized, the hemodynamics became stable, signs of "respiratory and heart failure" were stopped. Noted also positive dynamics of both laboratory and echocardiographic parameters: glucose 4.8 mmol/l; urea-13,71 mmol/l; residual nitrogen-4.2 mmol/l; total bilirubin - of 6.96 mmol/l; direct bilirubin-abs; indirect bilirubin-of 6.96 mmol/l; total protein-54 g/l; ALT-1.05 mmol/l; AST-0.36 mmol/L. According echocardiography: EF-81%; KDO-76,0 ml; IVS-1.4 cm; Ssli-1.5 cm; heart rate-77 BPM Cavity of the heart is not enlarged, heterogeneous folds, edge sealed. In the pericardial cavity, anechoic areas are not identified, the IVS hypertrophy, and ssi. In both pleural cavities, the exudate is not detected.

The patient was discharged in satisfactory condition on 20/12/2018 with a recommendation to be monitored by specialists at the place of residence (cardiologist, pulmonologist, cardiac surgeon). The patient was re-examined 3 months after the operation, the general condition is satisfactory, does not show complaints, the general state of health is good.

## DISCUSSION

To date, treatment (EP) is preferred to minimally invasive surgery. Currently, operations are successfully performed in the pathology of the lungs, diaphragm, esophagus, pleura using the "thoroscopic technique." Endosurgical interventions in thoracic surgery have established themselves as a highly effective method of surgical treatment. [3,5] The indisputable advantage of minimally invasive operations is the low invasiveness of surgical access, a lower frequency of wound infection, a reduction of pain syndrome, which, in turn, contributes to a milder analgesia regimen in the postoperative period, early activation of patients, a decrease in the duration of hospitalization and lower financial costs for treatment [8,13,17]. Equally significant is the pronounced cosmetic effect after minimally invasive interventions compared to classical surgical approaches.

Various extrapleural accesses, thoroscopic pericardial

fenestration, and in some cases Subtotal pericardial resection via thoracotomy or sternotomy are used in the treatment (EP). In patients with "compression syndrome and tamponade of the heart", some researchers follow the following tactics. After confirming the diagnosis with echocardiography, it is recommended to perform a puncture and percutaneous drainage of the pericardium. Such manipulation minimizes the possibility of injury to the myocardium and coronary vessels since the time of finding the needle in the pericardial cavity is significantly reduced.

Another advantage of pericardial drainage is the ability to control pericardial fluid: if necessary, you can safely remove accumulated exudate, administer medications, and control intrapericardial pressure. Next, it is recommended to conduct a cytological examination of the fluid, computer tomography of the chest, after which a minimally invasive operation and an extrapleural pericardectomy or thoroscopic pericardial fenestration. Literature data [7,13,16] indicate that "thoroscopic pericardial fenestration" is indicated if serous or hemorrhagic exudate is obtained during pericardial puncture, and after an examination including a chest CT scan and cytological examination of the exudate, the question of the etiology of the disease remains unclear.

Also, "thoroscopic fenestration" is indicated if there is a pathological process in the pleural cavities and mediastinum that requires invasive diagnosis and surgical treatment. The researchers consider bilateral adhesions in the pleural cavities and respiratory failure of the 3rd degree to be a contraindication to "thoroscopic operations". The same researchers [1,6] in purulent pericarditis, the bilateral adhesive process in the pleural cavities, disseminated malignant process and in a severe condition of the patient, when it is not possible to perform thoracoscopy, recommend performing an extrapleural pericardiotomy and resection of the pericardium with pericardioscopy.

Of great importance in the diagnosis of the etiology of pericarditis is pericardioscopy [8], which allows you to solve three problems: direct visualization of the pericardial and epicardial regions of the pericardium/epicardium and video-assisted sanitation of the pericardial cavity. Pericardioscopy is of particular importance in video-assisted pericardial rehabilitation for purulent pericarditis. Direct visualization of remote areas of the pericardial cavity allows you to sanitize the pericardium by targeted washing and mechanical removal of purulent fibrinous masses. The main advantages of transpleural pericardioscopy are minimally invasive (two or three chest incisions of 5-10mm each) and the ability to perform thoracoscopy, pleural cavity sanitation, and targeted biopsy in the pleural cavity and mediastinum from the same access, which significantly increases the diagnostic value of the study.

Disadvantages of transpleural pericardioscopy include the need for artificial lung ventilation, including single-lung intubation of the patient, the ability to examine only a limited area of the pericardial cavity/epicardium on the access side, infection of the pleural cavity in purulent pericarditis. However, the study can not be performed with a bilateral adhesive process in the pleural cavities. In turn, extrapleural pericardioscopy is possible without intubation of the patient on spontaneous breathing. In this case, as a rule, it is possible to examine most of the pericardial cavity above the apex, above the right gastric and right atrium, the oblique sinus zone, only the zone above the lateral surface of the left ventricle and above the left atrium is inaccessible to inspection, except for the encysted accumulation of fluid.

At the same time, it is possible to sanitize a large part of the pericardial cavity, which is very important for purulent pericarditis, the study is possible with a bilateral adhesive process in the pleural cavities. At the same time, the disadvantages of extrapleural pericardioscopy are the inability to examine the pleural cavities and mediastinum. In case of relapse, it is possible to perform both thoracoscopy or extrapleural pericardiotomy, and Subtotal pericardial

resection. In the development of constrictive pericarditis, Subtotal resection of the pericardium is indicated.

#### CONCLUSION

In General, the successful experience of thoracoscopic pericardectomy presented by us in this clinical observation confirms the possibility, safety, and effectiveness of the thoracoscopic method in the treatment of exudative pericarditis with compression syndrome and the threat of cardiac tamponade. This success was evident thanks to the accumulated experience of thoracoscopic operations in the endosurgical center, as well as thanks to the participation of such specialists as endo surgeons, cardiac surgeons, thoracic surgeons and including anesthesiologists-resuscitators. This is the fourth case of successful treatment of "exudative pericarditis" in the center of endosurgery. In this clinical observation, the patient was treated based on a specialized Department of cardiovascular surgery. Such a multidisciplinary approach, in our opinion, is justified and justified, which could not but contribute to the recovery of this patient.

Thus, the case of clinical observation indicates that the diagnosis and treatment of "exudative pericarditis" with heart compression syndrome is quite difficult due to the danger of progression of heart and respiratory failure, as well as the threat of development of cardiac tamponade. In terms of diagnosing "exudative pericarditis" occurring with signs of heart compression, you should use informative and high-tech research methods (echocardiography, ultrasound, MSCT), which make it possible to perform a video thoracoscopic pericardectomy with a favorable outcome promptly. The use of thoracoscopic pericardectomy in the treatment of exudative pericarditis with heart compression syndrome may be a promising method, but further improvement of the intervention technique is required, as well as the study of long-term results.

#### REFERENCES

- Gilyarevsky S.R. Diagnosis and treatment of pericardial diseases: modern approaches based on evidence and clinical experience. M.: Mediasphere, 2004. 132.
- Gogin E.E. Diseases of the pericardium. M.: Medicine, 1979. p. 192.
- Razumovsky A.Yu., Mitupov ZB Endosurgical operations in thoracic surgery in children: hands. Moscow, Russia: GEOTAR-Media; 2010.304 p.
- Soloviev G.M. Endoscopic pericardectomy with effusion pericarditis. *Cardiology* 1993; 4: 38-40.
- Thoracic surgery: a guide / under. ed. L.N. Bisenkova. St. Petersburg: Hippocrates, 2004.p. 927.
- Agrawal V., Saxena A., Sethi A., Acharya H. Thoracoscopic pericardectomy for management of purulent pneumococcal pericarditis in a child. *Asian J Endosc Surg*. 2012 Aug; 5(3): 145-48.
- Augustin P, Desmard M, Mordant P, Lasocki S, Maury JM, Heming N, et al. Clinical review: intrapericardial fibrinolysis in management of purulent pericarditis. *Crit Care*. 2011 Apr 20;15(2):220. doi: 10.1186/ cc10022.
- Besit N., Unlu Y., Ceviz M., Kocagullari C.U. et al. Subxiphoid pericardiostomy in the management of pericardial effusion: case series analysis of 368 patients. *Heart*. 2005; 91:785-790.
- Cakir O, Gurkan F, Balci AE, Eren N, Dikici B. Purulent pericarditis in childhood: ten years of experience. *JPediatr Surg*. 2002 Oct;37(10):1404-8.
- Dupre GP, Corlouer JP, Bouvy B. Thoracoscopic pericardectomy performed without pulmonary exclusion in 9 dogs. *Vet Surg*. 2001 Jan-Feb;30(1):21-7.
- Fibla J.J., Molins L., Mier J.M., Vidal G., Pericardial window by videothoracoscope in the treatment of pericardial effusion and tamponade. *Cir Esp*. 2008 Mar; 83(3): 145-148.
- Jackson J., Richter K.P., Launer D.P. Thoracoscopic partial pericardectomy in 13 dogs. *J Vet Intern Med* 1999 Nov-Dec; 13(6): 529-33.
- Liem N.T., Tuan T., Dung le A. Thoracoscopic pericardectomy for management of purulent pericarditis: experience with 21 cases. *J Laparoendosc Adv Surg Tech A*. 2006 Oct; 16(5): 518-21.
- Maisch B., Risti A.D., Seferovi P.M., et al. Guidelines on the Diagnosis and Management of Pericardial Diseases Executive Summary. The Task Force on the Diagnosis and Management of Pericardial Diseases of the European Society of Cardiology. Executive summary. *Eur Heart J* 2004; 25:587-610.
- Ohtsuka T, Takamoto S, Nakajima J, Miyairi T, Kotsuka Y. Minimally invasive limited pericardectomy: the hybrid approach. *Ann Thorac Surg*. 2000 Oct;70(4):1429-30.
- Pankuweit S, Risti AD, Seferovi PM, Maisch B. Bacterial pericarditis: diagnosis and management. *Am J Cardiovasc Drugs*. 2005;5(2):103-12.
- Tsang T.S., Enriquez-Sarano M., Freeman W.K., et al. Consecutive 1127 therapeutic echocardiographically guided pericardiocenteses: clinical profile, practice patterns and outcomes spanning 21 years. *Mayo. Clin. Proc*. 2002; 77(5):429-436.
- Walsh P.J., Remedios A.M., Ferguson J.F., Walker D.D., Cantwell S., Duke T. Thoracoscopic versus open partial pericardectomy in dogs: comparison of postoperative pain and morbidity. *Vet. Surg*. 1999 Nov-Dec; 28(6):472-479.
- Hasamnis AA, Patil SS, Shaik Imam, Narendiran K. "A Review of Pharmacoeconomics: the key to "Healthcare for All"." *Systematic Reviews in Pharmacy* 10.1 (2019), s40-s42. Print. doi:10.5530/srp.2019.1s.21
- Hassanzadeh, J., Mohammadbeigi, A., Eshrati, B., Moemenbellah-Fard, M. Estimation of the regional burden of non-communicable diseases due to obesity and overweight in Markazi province, Iran, 2006-2007(2012) *Journal of Cardiovascular Disease Research*, 3 (1), pp. 26-31.  
DOI: 10.4103/0975-3583.91600