

SPECIAL PATHOMORPHOLOGICAL CHANGES IN CHILDREN WITH LYMPHOCYTIC LEUKEMIA

¹Zulfiya Salayeva, ²Roza Masharipova, ³Parokhat Aliyeva, ⁴Gulsara Jumanyazova, ⁵Gulnora Shamuratova

¹Assistant of Department of Hospital and Outpatient Pediatrics of Urgench Branch of Tashkent Medical Academy, Uzbekistan.

²Senior Lecturer, Department of Hospital and Outpatient Pediatrics of the Urgench Branch of Tashkent Medical Academy, Uzbekistan.

³Assistant of the Department of Hospital and Outpatient Pediatrics of the Urgench Branch of Tashkent Medical Academy, Uzbekistan.

⁴Senior Lecturer, Department of Hospital and Outpatient Pediatrics of the Urgench Branch of Tashkent Medical Academy, Uzbekistan.

⁵Candidate of Medical Sciences, Senior Lecturer, Department of Neurological and Mental Diseases Urgench Branch of Tashkent Medical Academy, Uzbekistan.

E-mail address: article_01@mail.ru

Received: 04.12.2019

Revised: 02.01.2020

Accepted: 09.02.2020

Abstract

First of all, leukemia cells appear in the organ stroma, then infiltrate the parenchyma. Acute lymphoblastic leukemia in children is the most common cancer in children aged 2-5 years. The main clinical and morphological sign is the large production of lymphocytic cells from the bone marrow. The disease is very severe and often leads to death. It is therefore important to identify and recognize the initial signs of the disease. Every year, 50 out of a million children are infected with the disease. Blood and lymph tissue tumours account for half of all malignant tumours, of which between 38 and 40% are leukemia. Of the 100,000 children under the age of 15, 4.1 ± 0.4 suffer from acute lymphocytosis, with boys and girls at a ratio of 1.3 to 1, and 2 to 5 years at most. Modern diagnosis of acute lymphocytosis is based on the FAB classification, whose main criterion is morphological and cytological confirmation of blood vessels. In the sample of bone marrow from 25 to 30% of blasts were diagnosed with acute leukemia, with 3 types of cells identified: L1, L2, L3. 85% of acute lymphoblasts were L1, 14% L2, and 1% L3. The main diagnostic method is cytomorphology. Trepan biopsy should be obtained from the iliac bones, and the diagnosis is confirmed by the presence of poorly differentiated blast cells in the histological preparation.

Key words: path morphological, lympholecrosis, tissue tumours, cytomorphology, lymphocytic, polyclinic.

© 2019 by Advance Scientific Research. This is an open-access article under the CC BY license (<http://creativecommons.org/licenses/by/4.0/>) DOI: <http://dx.doi.org/10.31838/jcr.07.04.71>

INTRODUCTION

The aim was to study the path morphological changes in lympholecrosis in children. Lympholecrosis in children is manifested by the appearance of focal leukemic infiltrates in the bone marrow and all lymphatic organs. Depending on the origin of lympholecrosis from T, or from B lymphocytes, leukemic infiltrates are localized in T or B zones.

MATERIALS AND METHODS

To achieve this goal, over the past 10 years (2009-2018) the National Institute of Hematology and Blood Transfusion has been studying the material for the autopsy of children who died of lymphocytosis. During this time, the Institute's polyclinic treated 2568 sick children with lymphocytic leukemia, 84 of whom died. Of these, 37 were girls and 47 were boys. By age: 12 died before the age of 2 years, 28 died before the age of 4 years, 26 died before the age of 6 years and 18 died before the age of 10 years. The deceased's medical history, laboratory data, autopsy report and internal organ fragments were analyzed, their histological preparations were examined under a microscope, and photographs and details were taken.

RESULTS OF RESEARCH

The bone mass study, which was based on the study of bone mass, revealed that, depending on the level of leukemia, the blanket leukemia cells, if lightly shaped, were concentrated in foci and in severe form infiltrated almost all bone burial sites. Hypoplasia of blood vessels, necrosis and other bone marrow cells are often found.

Thymus. A feature of lymphocytic leukemia in children is that in almost all cases, the thymus has grown to some extent, and in some cases weighs about 30 grams. The slices appeared to be almost the same size, in a soft grayish-gray colour, in some cases the pieces were bound together and small blood vessels appeared on the surface. When examined under a microscope, thymus slices were of different sizes, with enlarged tissue and leukemia cells appeared around the blood vessels. It was noted that the thymus parenchyma was infiltrated by leukemia cells only in T-lymphocytes. At the same time, the slice lining was slightly enlarged, which revealed diffuse leukemia cells (Fig. 1). The mucous membrane is concentrated only around the blood vessels, Gassal's bodies were enlarged and the number of necrosis in the body was increased.

Spleen. In most cases, the weight of the spleen was 2-3 times higher than normal, and in some patients it weighed 750 grams. The shape of the organ was rounded, the outer part was thickened, the color pale and thicker, the tissue was compressed, and the white and red flesh did not differ. Under a microscope it was found that leukemia cells initially began to accumulate in the periphery of the white spleen pulp. Later, the lymph follicle was found to occupy a ring of lymphocytes and even enter the germ area. Another finding was that leukemia cells were invaded into the per articular T-region only in some cases. Thus, it can be concluded that leukemia only enters this area if T develops from lymphocytes (Fig. 2), whereas in B-lymphocytic leukemia, leukemia cells are mostly concentrated in lymphatic follicle regions. In most cases, leukemia cells were found to infiltrate the diffuse tubules of the red pulp.

Lymph nodes. Another feature of lymphocytosis in children is that lymph nodes are not always able to grow. In most cases, lymph nodes are anatomically close to normal. Only in isolated cases have lymph node enlargements of a certain anatomical region been detected. Although lymph nodes are enlarged, their texture is purple red without soft contact. Under a microscope, it was found that leukemia cells were first collected around the peripheral sinus node and then inside the sinusoidal and intermediate glandular tissue. It was also found that if leukemia develops from T-lymphocytes, the paracortical region is significantly expanded by diffuse infiltration of leukemia cells (Fig. 3). Only in some cases the mucous membrane of the lymph node manifested itself by infiltration of lymph follicles by leukemia cells due to its shape and disturbed morphofunctional areas.

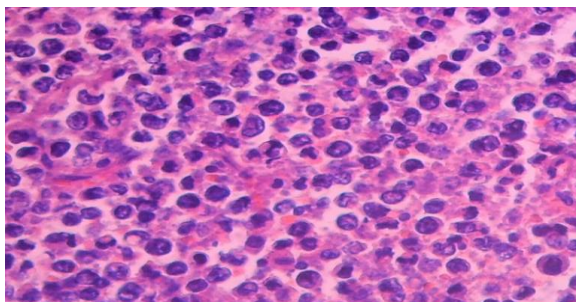
The liver. Liver is slightly enlarged, color light brown, soft, with grayish-gray cavity and stripes appear in tissue. Under microscope, leukemia cells were mainly concentrated in the Disse cavity, i.e. around and around sinusoidal wall (Fig. 4), and in some cases even around central vein. As a result, hepatocytes slightly disrupted their trabecular structure and parenchymatous protein in cytoplasm, vacuoles in some areas, hyaline-water dysfunction in other places.

DISCUSSION

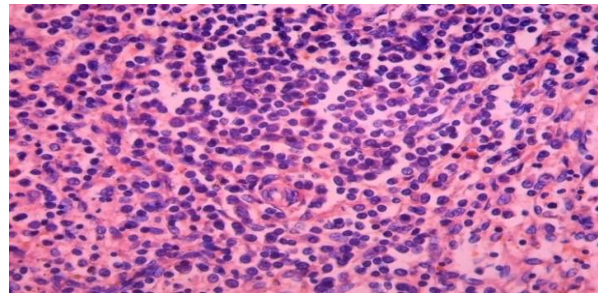
It should be noted that pathomorphologically specific signs of lymphocytic leukemia in children are bone marrow, thymus, spleen, lymph nodes and even liver (1,4,7). In the bone marrow, the disease is most often manifested by fistula leukemia infiltration, which is different from other types of leukemia. In the thymus, the data are clear: leukemia infiltration, mainly in T-lymphocytic leukemia, begins with intermediate thymus tissue and then spreads to parenchyma, often leukemia infiltration of the cortex. Specific pathomorphological changes in the spleen are that, depending on the type of lymphocytic leukemia, T-lymphocytic leukemia is predominantly a marginal area, and in the periarticular area subjected to leukemic infiltration, changes in B-lymphocytic leukemia are followed by complete lymph follicles. Depending on the type of leukemia in lymph nodes, leukemic infiltration in T-lymphocytes predominates in the paracortical region, whereas in B-lymphocytosis most of the lining is covered by leukemic infiltration of the cortical follicles. In both types of lymphocytosis, small changes are observed in the liver, mainly with perisinusoidal mission and central venous leukemia infiltration.

CONCLUSION

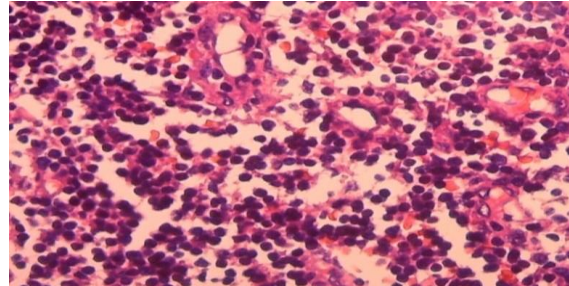
1. Child lymphocytic leukemia is pathomorphologically characterized by bone burial and leukemia infiltration in almost all lymphatic organs at the beginning of the disease.
1. Lymphocytic leukemia is characterized by leukaemic infiltration in certain areas of the lymphatic organs, depending on whether T or B develops from lymphocytes.
2. Pathomorphological changes in lymphocytic leukemia first appear in the stroma vascular structures of the organs, and then extend to the parenchyma.



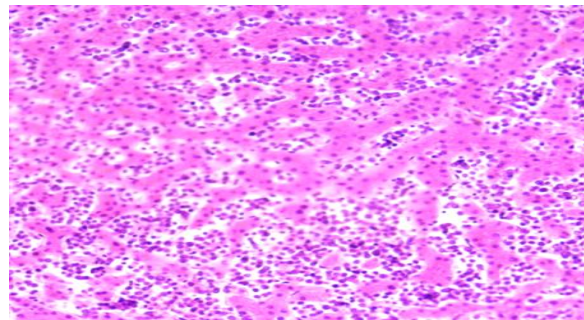
Picture 1. Timus. Lymphoblastic leukemic infiltration. paint: G-E. X: 10 x 40



Picture 2. Leukemic infiltration in the periarterial area. paint: G-E. X: 10 x 20



Picture 3. Lymph node Leukemic infiltration of paracortical industry. paint: G-E. X: 10 x 40



Picture 4. Liver Leukemic infiltration of the dissein space. paint: G-E. X: 10 x 20

REFERENCES

1. Alekseev N.A., Vorontsov I.M. Leikoz at children L.: Medicine. 1989, p.247.
2. Vladimirskaia E.B., Rumantsev A.G. Hematopoietic skin differentiation of differentiated potentials. // Hematology / Oncology and immunology in pediatrics. 2002. M. T. 1, № 1, p.7-11.
3. Vladimirskaia E.B. Torubarova N.A. Ostrie leukemia and Gpoptasia carpet-making is in detail. M.: Honey. 1985, p. 209.
4. Vladimirskaia E.B. Factors of Reality in the Field of Real Estate. Shkn.: Biological bases of antitumor therapy. Vladimirskaia E.B., Moscow, 2001, p. 33-58.
5. Karachunsky A.I. Strategies of therapy of lymphatic leukemia. 1999, p.54.
6. Makhonova L.A., Mayakova S.A., Peterson I.S., Tupitsin N.N. Diagnostics and leukemia in children at the present stage // Pediatrics. -1991.- № 11, p. 54-58.
7. Makhonova, L.A.; Gavrilova, I.E.; Mayakova, S.A. I am Doctor of biological reactions modification and programmed treatment with leukemia and lymphocytic lymphoma. // Children oncology. 1995. - № 2-3. p. 27-30.
8. PV Kamala Kumari, S Akhila, Y Srinivasa Rao and B. Rama Devi. "Alternative to Artificial Preservatives." Systematic Reviews in Pharmacy 10.1 (2019), 99-102. Print. doi:10.5530/srp.2019.1.17