

Improvement of Surgical Treatment of Acute Hematogenous Osteomyelitis of the Bones of the Hip Joint in Children

¹Jamshid Shamsiev, ²Azamat Shamsiev, ³Zafar Makhmudov, ⁴Sukhrob Zainiev, ⁵Karshiboy Boboyarov, Jasur Ruziev, ⁶Firdavs Khurramov

^{1,2,3,4,5,6}Samarkand State Medical Institute, Republic of Uzbekistan

Received: 16 March 2020 Revised and Accepted: 17 June 2020

Abstract

The goal of the work was to improve the results of treatment of acute hematogenous osteomyelitis of the bones of the hip joint (CSF KTS) by improving surgical methods. To solve this problem, we examined and treated 134 children with CSO CSF aged 6 to 18 years. According to the type of surgical interventions, patients with CSF CTS are divided into two clinical groups. Group 1 consisted of 53 (39.6%) children who received conventional surgical treatment, group 2 consisted of 81 (60.4%) children who had an autopsy performed by draining osteoperforation of the acetabulum roof. A comparative analysis showed that the greatest number of complications in the long term after discharge of patients from the hospital was noted in the first group. The above allows us to recommend DKVV as a highly effective method of treating CSO CSW in children.

KEYWORDS: CSF KTS, CSO CSF, DKVV

I. Introduction

Early diagnosis, timely treatment started often determine a favorable outcome of the pathological process and prevent disability of the child [4]. Despite the advances in modern surgery, traumatology and orthopedics, many issues of therapeutic tactics in acute hematogenous osteomyelitis of the bones of the hip joint (CSF CT) remain debatable. So, generally accepted objective criteria for early diagnosis have not been developed, the effectiveness of existing methods of surgical treatment is insufficient, especially in children, which, with minimal trauma, allows achieving the most complete sanitation of the lesion.

The main method of treating CSO CSF, as you know, is the surgical method. To date, most authors are convinced that in the surgical treatment of CSF CSF, efforts should primarily be aimed at sanitizing the purulent focus and thorough immobilization of the affected limb [2, 3]. Decompression, drainage and sanitation of the site of purulent infection in the bone are crucial for a favorable outcome in acute hematogenous osteomyelitis [5, 6]. When choosing the method of operation and surgical access, localization of the focus, age of the patient, prevalence and phase of the pathological process are taken into account [1].

The main requirements for local treatment of CSF CSF should be: simplicity of execution, complete decompression and radical removal of pus from the lesion without secondary infection of soft tissues, sparing access and creating favorable conditions for regenerative processes of bone tissue, ensuring optimal functional outcome [7].

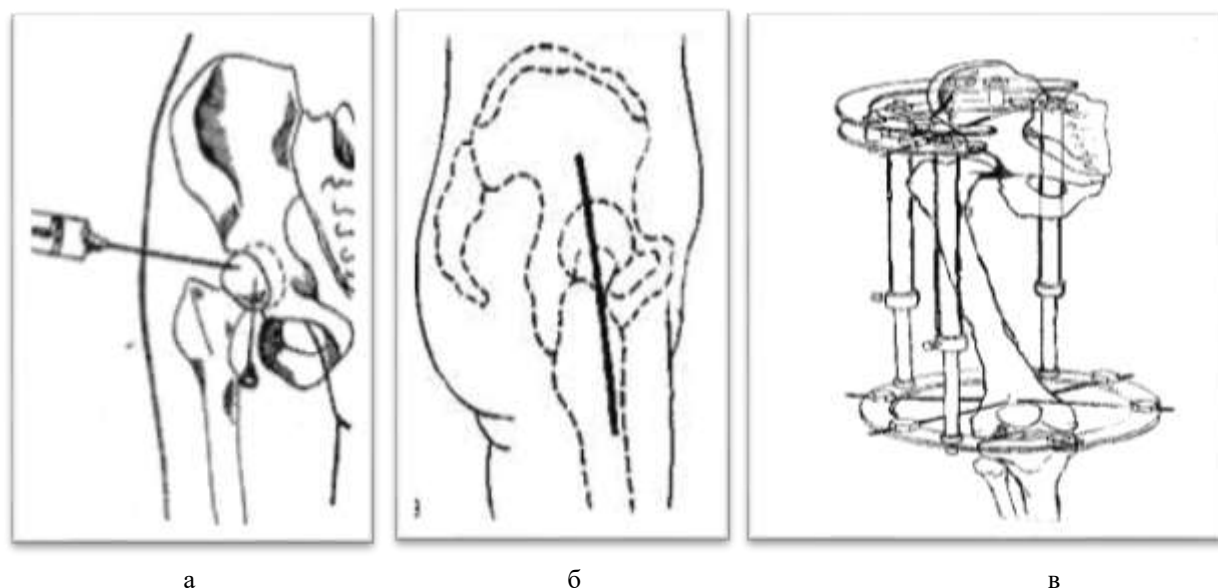
The aim of our study was to improve the results of treatment of CSO CSF by improving surgical methods.

II. Material and Methods:

In order to solve this problem, we examined and treated 134 children with CSOs from 6 to 18 years old who were hospitalized in the purulent surgery department of the 2-clinic of the Samarkand State Medical Institute for the period from 1991 to 2018. The main number of patients with CSO CSF turned out to be between 10 and 14 years old - 75 (56%), i.e. during a period of increased physical activity and active growth of the skeletal system. Boys were 96 (71.6%), girls - 38 (28.4%).

By the type of surgical procedures performed, 134 patients with CSO CSF are divided into two clinical groups. The first group consisted of 53 (39.6%) children conditionally divided into two groups. 1a, a group of 33 children from 1991 to 2000 who received conventional surgical treatment - after a TS puncture and if they received purulent exudate, then performed an arthrotomy of the hip joint according to Guter (front access).

Group 1b, to 20 patients from 2000-2003, in the light of the achievement of modern medicine, the next step to prevent orthopedic complications in patients with CSF CT, after arthrotomy, the TC region was fixed using the original technique using the Ilizarov apparatus instead of skeletal traction and immobilization of a coxite plaster cast (Patent for the invention of RUz IAP No. 03081) (Fig. 1).



a

б

B

Fig. 1. Puncture of the vehicle (a), access according to Guter (b) and extrafocal distraction osteosynthesis by the Ilizarov apparatus (scheme).

The second group consisted of 81 (60.4%) children who had an autopsy performed by the method of draining osteoperforation of the acetabular roof (DOKVV) (patent for invention RUz IDP No. 05082) (Fig. 2).

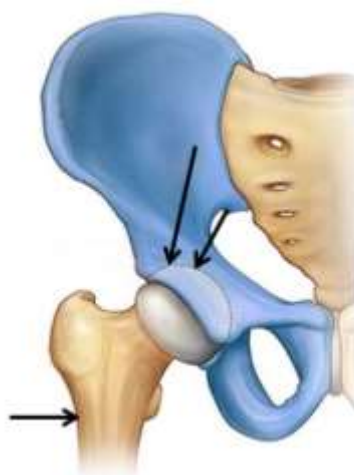

Fig. 2. Draining osteoperforation of the roof of the acetabulum (diagram).

III. Results and Discussion

The application of the proposed methods of surgical treatment of CSO CSF allowed to significantly reduce the duration of the period of hyperthermia with $9,12 \pm 0,87$ till $3,36 \pm 0,19$ days in 2. Also significantly reduced and the length of stay of patients in the hospital with $42,29 \pm 2,96$ till $22,64 \pm 0,83$ bed days in group 2. Moreover, children from this group were discharged for outpatient treatment without a plaster immobilizing dressing, with completely healed wounds. Mortality in the first group was 9.1%, in the second group there were no fatal cases (Table 1).

Table 1. The main results of the treatment of children with CSO CSL in various groups

Indicators	First group, n=53		Second group n=81
	1a, n=33	1б, n=20	
period of hyperthermia (days)	$9,36 \pm 0,88$ $p < 0,05$ $p_1 < 0,05$	$5,60 \pm 0,30$	$3,57 \pm 0,18$
bed days	$43,18 \pm 3,08$ $p < 0,05$	$29,6 \pm 2,51$	$22,89 \pm 0,66$

	$p_1 < 0,05$		
Mortality	3 (9,1%)	-	-

Note: p-significance of differences compared with subgroup 1b;

p1-significance of differences compared with group 2.

When applying the traditional method with the installation of Kirschner spokes when fixing the femoral neck with CSF CTS, children experienced various complications in the long-term treatment period (Table 2). The course of CSF CCC with late treatment (5-7 days) was complicated by the addition of a secondary infection. Pneumonia, including destructive, was observed in 22 patients (66.7%), metastases to other bones were observed in 5 (15.1%), purulent foci in soft tissues in 14 (42.4%), bedsores were observed in 9 (27, 3%) patients. During treatment in 6 (18.2%) cases, despite the fact that the femoral neck was fixed with Kirschner spokes, a pathological fracture of the femoral neck with a dislocation was noted. In group 2, the percentage of the above complications was significantly lower.

Table 2. The incidence of complications in children with CSF CSI depending on the methods of surgical treatment

Complications	First group, n=53				Second group, n=81	
	1a, n=33		1B, n=20		abs	%
	abs	%	abs	%		
pneumonia	22	66,7	14	70,0	32	39,5
purulent foci in the soft tissues	14	42,4	3	15,0	2	2,5
metastases to other bones	5	15,1	1	5,0	2	2,5
Myocarditis	9	27,3	5	25,0	2	7,4
Pressure sores	9	27,3	4	20,0	-	-
Pathological fracture, dislocation	6	18,2	11	55	-	-

Of 134 patients with CSO CSF, long-term treatment results were studied in 104 (77.6%) patients from 1 year to 28 years after discharge from the hospital. Including in 45 (84.9%) patients of the first group, and in 59 (72.8%) of the second group. The outcomes of treatment of CSF CTS were traced in terms of 1-2 years in 4.5%, 3-5 years in 7.5%, 6-15 years old - 29.8%, 16 years old and above - in 35.8% of patients (Table 3).

Table 4: Dates of follow-up observation of patients with CSO CTS in various groups

groups	observation period, years				In total
	1-2	3-5	6-15	16 и выше	
1-я, n=53	2(3,7%)	-	5(9,4%)	38(71,7%)	45(84,9%)
2-я, n=81	4(4,9%)	10 (12,3%)	35(43,2%)	10(12,3%)	59(72,8%)
In total, n=134	6(4,5%)	10(7,5%)	40(29,8%)	48(35,8%)	104(77,6%)

The following parameters served as criteria for evaluating the results of treatment of CSF CSF: the patient's presence or absence of complaints, examination data, the presence or absence of orthopedic complications (ankylosis of the hip joint, fracture of the femoral neck and pathological dislocation, pelvic deformity), state of limb function. We took into account the transition of the disease into a chronic form (the presence of pain, fistula, relapse, etc.) and clinical and radiological restoration of the bone structure of the affected bones.

Characterization of complications in the long term after treatment of CSO CTS in children, depending on the method of treatment.

Complications	1 group (n=53)	2 group (n=81)	In total
Ankylosis	31 (58,5%)	16 (20%)	47
dislocation of the femur	18 (34%)	9(11,1%)	27
femoral neck fracture	12(22,6%)	5(6,2%)	17
pelvic deformity	24 (45,3%)	8(9,9%)	32
transition to a chronic form	31 (58,5%)	-	31

Note: some patients had 2-3 complications at a time.

A comparative analysis showed that the greatest number of complications in the long term after discharge of patients from the hospital was noted in the first group, where ankylosis of the hip joint was observed in

58.5% of patients. In the second group, where DECV was used as a surgical treatment, the percentage of ankylosis was significantly lower - 20%. The same trend was characteristic when comparing other complications: pathological dislocation of the femur in the 1st group - 34%, in 2 - 11.1%; fracture of the femoral neck in group 1 - 22.6%, in 2 - 6.2%; pelvic deformity in group 1 - 45.3%, in 2 - 8.9%; transition to the chronic form in group 1 - 58.5%, in group 2 - was not detected.

IV. Conclusions

Our proposed method of draining the lesion, which does not cause excessive trauma to the tissues surrounding the hip joint, makes it possible to put patients on their feet in a relatively short period of time after recovery. It should be noted that the advantages of this method are reliably manifested, both in the early postoperative and in remote periods of medical and social rehabilitation. The above allows us to recommend DKVV as a highly effective method of treating CSO CSW in children.

V. References

1. Akberov R.F., Lyyurov D.A., Svarich V.G. Acute hematogenous osteomyelitis in children // *Pediatric Surgery*. 2016; 20 (4). - S. 200-203
2. Bogonosov A.Yu., Stalmakhovich V.N. et al. A new approach to the treatment of acute hematogenous osteomyelitis of the femoral neck // *Osteomyelitis in children: abstract. doc. Russian Symposium for children Surgery - Izhevsk, 2006.* - S. 34-36.
3. Garkavenko Yu.E. Orthopedic effects of hematogenous osteomyelitis of long tubular bones in children (clinic, diagnosis, treatment): Author. dis. Dr. med. - SPb., 2011. -- 55 p.
4. Gilmutdinov M.R. Acute hematogenous osteomyelitis in children (literature review) / M.R. Gilmutdinov [et al.] // *Modern art of medicine.* - 2013. - No. 1 (9). - S. 73–80.
5. Tsap N.A., Chernenko L.Yu. Therapeutic tactics for osteomyelitis of flat bones in children // *Russian Bulletin of Pediatric Surgeons, Anesthesiology and Resuscitation*, 2011, No. 4. - P. 61-72.
6. Shestakov A.A. Modern opportunities for the early diagnosis of acute hematogenous osteomyelitis in children and effective treatment of patients. Abstract, Cand. honey. Sciences - Moscow, 2013, p. 3-4.
7. Sinikumpu J.J., Tapiainen T., Korhonen J., Perhomaa M., Serlo W. Acute hematogenous osteomyelitis in children *Duodecim*. 2014. V. 130, № 16. P. 1591–1598.