JOURNAL OF CRITICAL REVIEWS
ISSN- 2394-5125 VOL 9, ISSUE 05, 2022

Small Intestine

Muralinath E[1], Sravani Pragna K[1], Kaylan Chapalamadugu[1], Jaya Surya S[1], Guru Prasad M[2], Sri Devi V[3]
[1]College of veterinary science, proddatur, Andhra Pradesh, India.
2. Vaishnavi microbial pvt.ltd, Telangana, India.
3. Dept of bioscience, Mohan Babu University, Tirupathi,India.

Functional anatomy:

Small intestine seen between pyloric sphincter of stomach and ileocecal valve which gains entry into large intestine. It is also termed as small intestine due to its small diameter compare to that of large intestine. But it is larger than large intestine. Its length is approximately 6 meters. The physiological function-function of small intestine related to absorption. The absorption of digested food products occur to the maximum extent in small intestine. Small intestine contains three portions such as proximal part termed as duodenum, middle part termed as jejunum and distal part termed as ileum. The wall of small intestine contains four layers just like stomach.

Intestinal villi and glands of small intestine:

Intestinal villi:

The mucous membrane of small intestine is surrounded by minute projections termed as villi. The height of the villi is approximately 1mm and the diameter is less than 1 mm only. The villi is surrounded by columnar cells which are termed as enterocytes. Hair like projects are derived from each enterocyte. Hair like projections also termed as microvilli. The villi and microvilli enhances the surface area of mucosa by many folds. Within each villus, there is a central channel known as lacetal. The lacetal gains open into lymphatic vessels. It also contains blood vessels.

Crypt's of lieberkuhn or intestinal glands:

These are simple tubular glands of intestine.

Intestinal glands do not penetrate the muscularis mucosa of the intestinal wall, but open into the lumen of intestine between the villi. Intestinal glands are lined by columnar cells. Lining of each gland is continuous with epithelial lining of the villi epithelial cells lining the intestinal glands undergo division by mitosis at a faster rate. Newly formed cells push the older cells upward over the lining of villi. These cells which move to villi are called enterocytes. Enterocytes secrete the enzymes. The continuous shedding of the older enterocytes takes place into lumen along with enzymes. 3 types of cells are placed between columnar cells of the glands.

1. Argentaffin are other wise known as enterochromaffin cells. These cells secrete intrinsic factor that is responsible for absorption of vitamin B12.

2.Goblet cells secrete mucosa.

3.Paneth cells secrete cytokines and these cytokines are termed as defensins.

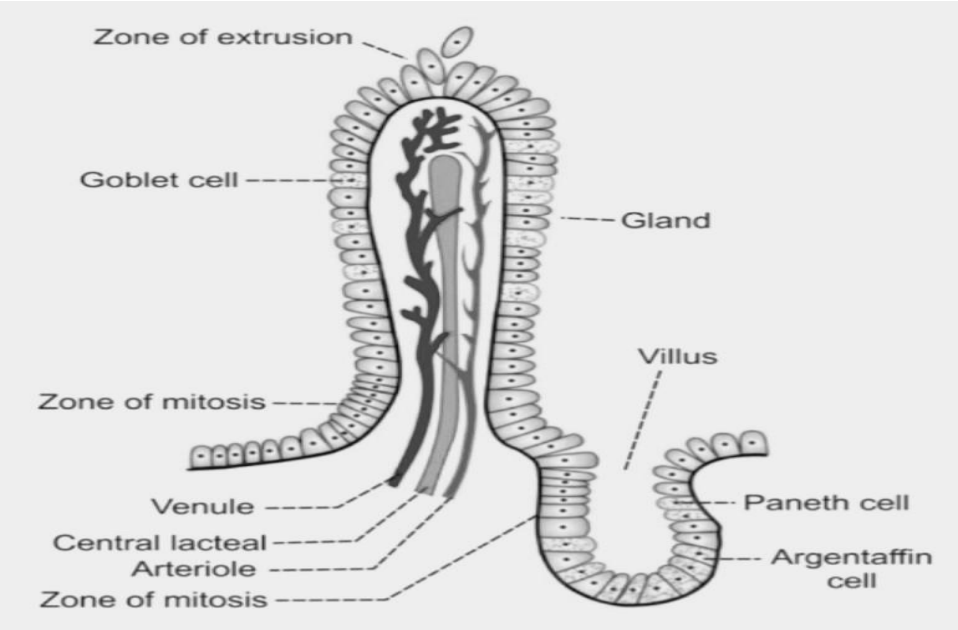

Brunner's Glands:

In additional to intestinal glands, the first part of duodenum consists of a very few mucus glands which are termed as Brunner glands. The penetration of these glands occurs into muscularis mucosa and expands till the submucosa coat of the intestinal wall. The Brunner's glands are opened into the lumen of intestine straightly. Brunner's glands secrete mucus as well as trace of enzymes.

Properties and composition of Succus entericus:

Secretion from small intestine is also termed as succus entericus.

Properties of Succus entericus:

pH : 8.3

Reaction : Alkaline

Volume : 1800 mL/day

Composition of Succus entericus:

The succus entericus consists of water and solids. Solids include organic and inorganic substances. The concentration of bicarbonate is slight more in Succus entericus.

Functions of Succus entericus:

1.Activator factor:

The enterokinase observed in intestinal juice enhances the conversion of trypsinogen into trypsin. Trypsin again activates other enzymes.

2.Digestive function:

The enzymes of Succus entericus shows their activity on partially digested food and change them into final digestive products. The production and release of the enzymes happens into Succus entericus by enterocytes of the villi.

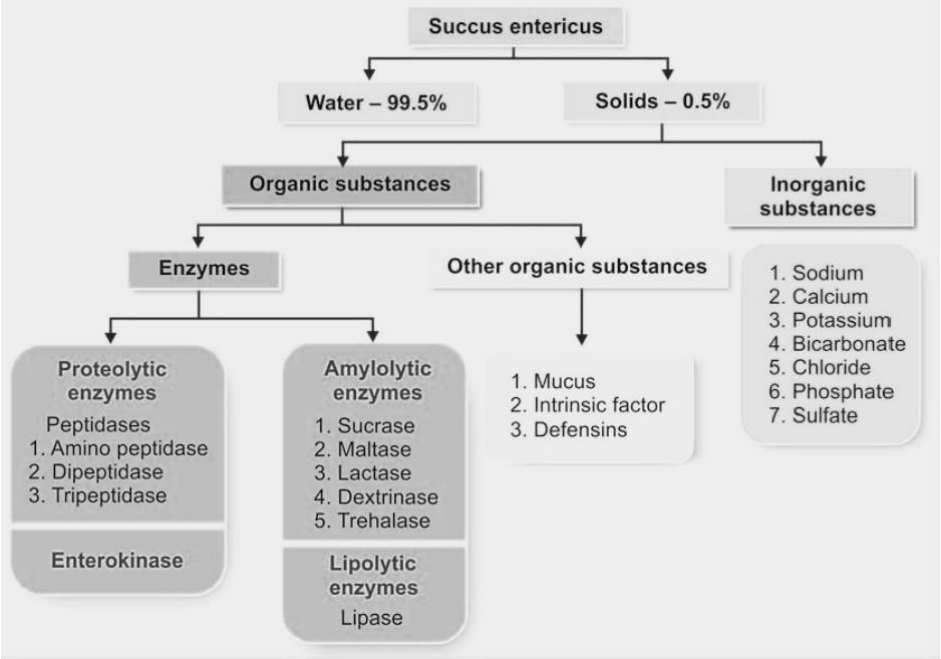

Amylolytic enzymes:

The carbohydrates splitting enzymes of Succus entericus are given in above fig. Lactase, maltose and sucrose change the disaccharides into two molecules of monosaccharides. Dextranase changes dextrin,altose and maltriose into glucose. Trehalose glucohydrase is responsible for the hydrolysis of trehalose and changes into glucose.

Proteolytic enzymes:

The proteolytic enzymes observed is Succus entericus are the peptidase which are listed in above fig. The peptidase change peptides into amino acids.

Lipolytic enzymes:

Intestinal lipase shows its action as triglycerides and changes them into fatty acids.

3. Hemopoietic function:

The intrinsic factor of castle is observed in the intestine. It plays a major role in erythropoiesis.

4. Hydrolytic process:

Intestinal juice assists in all the enzymatic reactions of digestion.

Functions of small intestine:

1. Activatorfunction:

The enterokinas is involved in the conversion of trypsinogen into trypsin.

2. Absorptivefunctions:

The presence of villi and microvilli in small intestine enhances the surface area of mucosa. This facilitates the absorptive function of intestine. Digested products of foodstuffs, proteins, carbohydrates, fats and other nutritive substances such as vitamins, minerals and water are absorbed mostly in small intestine. From the lumen of intestine, these substances pass through lacteal of villi, cross the mucosa and enter the blood directly or through lymphatics.

3. Digestive function:

a. Amylolytic enzymes:

Lactase, maltase and sucrase change the disaccharides into two molecules of monosaccharides. Dextrin, maltose and maltriose are converted into glucose with the help of dextranase. Trehalose undergoes hydrolysis with the help of Trehalose or trehalose glucohydralase. Trehalose is involved in changing trehalose into glucose.

Proteolytic enzymes:

The peptidases are helpful in converting the peptides into amino acids.

Lipolytic enzymes:

Intestinal lipase shows its action on triglycerides and changes them into glucose.

4. Hemopoietic function:

The intrinsic factor of castle is observed in the intestine and plays a major role in erythropoiesis.

5. Hydrolytic function:

Intestinal juice is involved in all the enzymatic reactions of digestion.

6. Horomonal function:

Small intestine is capable of producing GI hormones namely CCK, Secretin etc.. These hormones control the movement of GI tract and secretory activities of small intestine and pancreas.

7. Mechanical function:

The mixing movements of small intestine are responsible for through mixing of chyme with the digestive juices namely succus entericus, bile and pancreatic juice.

8. Secretory function:

Small intestine is capable of secreting enterokinase, succus entericus and GI hormones.

a. In small intestine, the absorption of sodium occurs actively. It is essential for absorption of glucose, amino acids and other compounds with the help of sodium co transport.

b. In ileum, the absorption of chloride occurs actively in exchange for bicarbonate. The significance of this exchange is not clear.

c. An active absorption of calcium happens in upper part of small intestine.

d. The movement of water occurs in or out of the intestinal lumen till the osmotic pressure of intestinal contents becomes identical to that of plasma.

Absorption of vitamins:

The absorption of the most of the vitamins occurs in upper part of small intestine. The absorption of B12 takes place in ileum. The absorption of water soluble vitamins occurs at a rapid rate compare to fat soluble vitamins.

Regulation of secretion of Succus entericus:

The secretion of Succus entericus is controlled by both the nervous and hormonal mechanism.

Nervous regulation:

Simulation of parasympathetic nerves I'd responsible for the occurrence of vasodilation and enhances the secretion of Succus entericus. Stimulation of sympathetic nerves leads to vasoconstriction and reduces the secretion of Succus entericus. But, the role of these nerves in the regulation of intestinal secretion in physilogical conditions is not clear. Whatever it may be, the local nervous reflexes play a major role in enhancing the secretion of intestinal juice. If chyme enters the small intestine, the stimulation of the mucosa happens particularly by tactila stimuli as well as irritation. It is responsible for the development of local nervous reflexs which activate the glands of intestine.

Hormonal regulation:

If the chyme enters the small intestine, the intestinal mucosa is capable of secreting CCK, enterokinin and secretin which enhance the secretion of succus entericus by activating the intestinal glands.

Methods of collection of Succus entericus in man:

In man, the collection of intestinal juice occurs by using multi ileum tube. The insertion of the multi ileum tube occurs through nose or mouth, till the tip or this tube arrives the intestine. A line is drawn on the tube. The entrance of the top of the tube into the small intestine is specified, if this line comes near the mouth. The tube consists of three lumens. To the other two lumens, small balloon's are connected. The enlargement of the intestine occurs, if the inflation of these

ballon's takes place. Now, the collection of the intestinal juice happens through the middle lumen with the help of aspiration.

In animals:

THIRY LOOP:

A portion of intestine is segregated from the gut with help of incision particularly at both ends. The cut ends of the main gut are connected and the continuity is regained. The closure of one end of isolated segment occurs and other end is brought about through abdominal wall. It is also termed as Thiry loop or Thiry fistula.

THIRY VELLA LOOP:

Thiry Vella loop is the modified thiry loop. In this, a long segment of intestine is cut and segregated from the main gut. Both the ends of the segment are brought out through the abdominal wall. The cut ends of the small gut are joined.

Applied physiology:

1.Celiac disease:

Celiac disease is an auto immune disease manifested by the damage of mucosa and atrophy of villi in small intestine leading to the impairment of digestion and absorption. It is also termed as gluten sensitive enteropathy, celiac sprue and nontropical ***Cause:***

Celiac disease is caused by gluten. It is a protein observed in barley, oats, raye as well as other grains. Gluten is like a poison to individuals with celiac disease. The damage of the intestine occurs with more severity.

Features:

1. Abdominal pain
2. Depression
3. Diarrhoea
4. Irritability
5. Steatorrhea
6. Weight loss

2. Crohn's disease or enteritis:

It is a inflammatory bowel disease (IBD) manifested by inflammation of small intestine. Generally, it effects the lower part of small intestine and the ileum. The inflammation is responsible for the occurrence of diarrhoea as well as malabsorption.

Causes:

Crohn's disease occurs because of abnormalities of the immune system. The immune system reacts to a virus or a bacterium and leads to the occurrence of inflammation of intestine.

Features:

1. Abdominal pain
2. Delayed or stunted growth in children.
3. Diarrhoea
4. Malabsorption of vitamin
5. Rectal bleeding, anemia and fever
6. Weight loss.

3. Malabsorption:

Malabsorption is related to the difficulty regarding the digestion or absorption of nutrient from small intestine. It leads to the occurrence of negligency in absorbing either the specific substances namely, proteins, fats, carbohydrates and vitamins or some general non specific substances of food. Malabsorption affects growth as well as development of the body. It is also responsible for the occurrence of specific diseases.

4. Malabsorption syndrome:

Malabsorption syndrome is the condition manifested by the failure of digestion as well as absorption in small intestine. Malabsorption syndrome is generally caused by crohn's disease, celiac disease, steorrhea and tropical sprue.

5. Steatorrhea:

Malabsorption of fats is observed in steatorrhea. This condition is manifested by deficiency of pancreatic lipase.

6. Tropical sprue:

Tropical sprue is a malabsorption syndrome and it affects the residents or the visitors to tropical areas where the disease is epidemic.

Cause:

The cause for this disease is not clear and it maybe linked to infectious organisms.

Features:

1. Abdominal and muscle cramps.
2. Anorexia and weight loss.

3. Diarrhea

4. Indigestion.

References:

1.Gonsalves N. Eosinophilic Gastrointestinal Disorders. Clin Rev Allergy Immunol. 2019 Oct;57(2):272-285. [PubMed]

2.Barsouk A, Rawla P, Barsouk A, Thandra KC. Epidemiology of Cancers of the Small Intestine: Trends, Risk Factors, and Prevention. Med Sci (Basel). 2019 Mar 17;7(3) [PMC free article] [PubMed]